Sports Medicine
https://doi.org/10.1007/s40279-024-02165-3

CURRENT OPINION

Histological Definition of Skeletal Muscle Injury: A Guide to Nomenclature Along the Connective Tissue Sheath/Structure

Carles Pedret[1] · José Peña-Amaro[2] · Ramon Balius[3] · Tero Järvinen[4]

Accepted: 6 December 2024
© The Author(s), under exclusive licence to Springer Nature Switzerland AG 2024

Abstract

Recent years have seen the development of various classifications of muscle injuries, primarily based on the topographic location within the bone-tendon–muscle chain. This paper proposes an enhanced nomenclature for muscle injuries that incorporates histoarchitectural definitions alongside topographic classifications, emphasizing the importance of connective tissue damage characterization. A detailed understanding of the distinct anatomical and histological characteristics of tendon, aponeurosis, and fascia is essential for consistent terminology. Tendons, aponeuroses, and fasciae, while all composed of dense connective tissue, differ in collagen fiber orientation and structural organization. Tendons feature longitudinally aligned fibers suited for high tensile forces and muscle-to-bone connections. Aponeuroses have perpendicular collagen fiber layers, allowing for force distribution and support for both longitudinal and transverse traction. Fasciae exhibit loosely organized fibers providing flexibility and movement between muscles. The continuity and differences within the musculotendinous frameworks, particularly at the musculotendinous junction (MTJ), elucidate the higher frequency of injuries at these sites compared with tendons, highlighting the MTJ's role as a stress-absorbing 'safety valve.'

Key Points

- Dense connective tissue structures are highly implicated in muscle injuries in sports.
- There is still a lack of knowledge of the appropriate usage of common anatomical terms like tendon, aponeurosis, or fascia.
- By focussing on the histological characteristics, there is a layer of specificity added that can significantly refine the approach to diagnosis, prognosis, and treatment of sports-related muscle and tendon injuries.

✉ Carles Pedret
info@carlespedret.com

1 Clinica Diagonal, Sports Medicine and Imaging Department, Esplugues de Llobregat, Spain

2 Department of Morphological Sciences (Section of Histology), Faculty of Medicine and Nursing, Maimonides Biomedical Research Institute of Cordoba (IMIBIC), University of Cordoba, Córdoba, Spain

3 Sport Catalan Council, Generalitat de Catalunya, Barcelona, Spain

4 Tampere University and Tampere University Hospital, Tampere, Finland

1 Introduction

Based on the topographic location of the injury within the bone-tendon–muscle chain, several classifications of muscle injuries have been proposed in recent years [1–3]. We hereby propose that the nomenclature for muscle injuries should include a histoarchitectural definition [4], which describes the damage to connective tissue structures, in addition to

Published online: 18 December 2024

the topographic classification. As a result, the nomenclature ought to emphasize the injury's histoarchitectural characteristics in addition to its macroscopic anatomy.

Although extensive research has been conducted, there is still uncertainty among health care professionals on the appropriate usage of common anatomical terms like tendon, aponeurosis, or fascia. In order to gain clarity on this matter, that is, so we all speak the same language, it is important to first understand the distinct characteristics of each anatomical structure.

While all three are fibrous structures surrounding the skeletal muscle fibers, they differ in their macroscopic connections and how they interact with other elements. Specifically, a tendon acts as a cord or ribbon connecting a muscle to a bone; an aponeurosis functions as a broad expansion linking muscles together or attaching them to bones; and lastly, fascia behaves like a sheath enveloping either an individual skeletal muscle or a group of muscles.

2 Histological Definitions

From a histological standpoint, although the three structures are constituted by dense connective tissue, the difference lies in the orientation of collagen fibers. In fasciae, collagen fibers, although arranged compactly, are not oriented or organized (similarly to the epimysium) as its main function is to cover the muscle [5]. Conversely, collagen fibers are oriented in the direction of traction in both tendons and aponeuroses [6].

The structural difference between tendon and aponeurosis is based on the different directions of traction to which they are subjected. In tendons all collagen fibers are aligned in the same direction forming longitudinal fascicles allowing longitudinal traction. In aponeuroses they are arranged in overlapping planes where all fibers within the same plane are parallel to each other, while their orientation is oblique or perpendicular with respect to the adjacent plane which allows traction in both longitudinal and transverse directions [7].

Tendon The tendon is histologically defined as dense connective tissue with oriented collagen fibers (Fig. 1A). That is, all collagen fibers are oriented in the same direction of traction. This anatomical arrangement is critical as it enables the tendon to withstand high tensile forces, transferring the contraction forces from the muscle to the bone to produce movement. Injuries to tendons are often a result of overuse leading to conditions such as painful tendinopathy or traumatic, acute ruptures due to excessive tension. The tendons are relatively avascular and have a high tensile strength, with collagen fibers forming longitudinal fascicles that support longitudinal traction.

Aponeurosis Aponeuroses are similar to tendons in that they are also made of dense connective tissue but differ in their structure from tendons (Fig. 1B). They have layers of collagen fibers arranged in a flattened sheet, with each successive layer's fibers oriented perpendicular to the previous layer. This arrangement allows for the dispersal of force over a wider area and supports both longitudinal

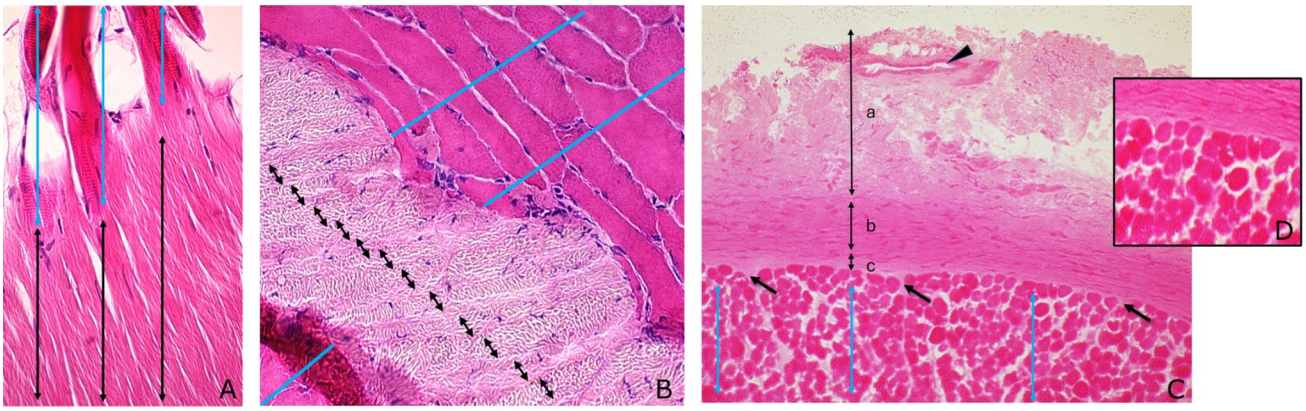

Fig. 1 Histology of tendon, aponeurosis, and fascia. **A** Tendon. Histological section at the level of a myotendinous junction showing the parallel arrangement of collagen fibers in the tendon. Among them are the nuclei of the tenocytes (fibroblasts). The blue arrows indicate the muscle fibers. The *black arrows* indicate the tendon. Hematoxylin–eosin dye, ×40. **B** Aponeurosis. Histological section clearly showing layered organization, with collagen fibers sectioned in various directions within (small black arrows) the aponeurosis. Between the collagen layers are the nuclei of fibroblasts. The blue arrows indicate the muscle fibers. Hematoxylin–eosin dye, ×40. **C** Fascia. Histological section displaying up to three different layers (thin black arrows) of a fascia surrounding the skeletal muscle. The first two (*a* and *b*) correspond to the fascia, while the deepest one (*c*) corresponds to the epimysium, which continues into the actual muscle with the beginning of the perimysial septa (thick black arrows). The blue arrows indicate the interior of the muscle. In layer (*a*), a vascular structure is observed (arrowhead). Hematoxylin-eosin dye, ×20. **D** Zoomed detail of the perimysial septa of the fascia presentation

and transverse traction, reducing the risk of injury due to this dispersion of stress.

Fascia Fascia is a fibrous connective tissue sheath that surrounds a skeletal muscle or muscle group (Fig. 1C). It does not have the same regular, organized structure of collagen fibers as tendons or aponeuroses. Instead, its fibers are loosely organized, allowing for more flexibility and movement between internal body structures. From a histological perspective, it presents two well defined layers. The outermost layer presents non-oriented collagen fibers with blood vessels and nerves, while in the inner layer the collagen fibers are more compact and oriented [8].

3 Continuity of Connective Musculotendinous Frameworks

Histologically, we currently understand that the epimysium is clearly continuous with the epitenon and the perimysium clearly continuous with the tendon, but the endomysium is not continuous with the epitenon [9]. We consider this anatomical detail very important for understanding why injuries are more frequent at the musculotendinous junction (MTJ) than in the tendon itself. In this context, the lack of continuity between the endomysium and the endotenon acts as a safety valve against the functional stress of the muscle; before a tendon rupture occurs, it is preferable to have a rupture at the MTJ, as this is easier to manage or heals better and faster than the tendon rupture.

4 Practical Application

In the context of sports, these differences influence the type and treatment of injuries. First of all, it was recently demonstrated that injuries to proximal tendons of the biceps femoris take almost 2.5 times as long to heal as injuries occurring in the central aponeuroses of the hamstring muscle [10]**.** Furthermore, involvement of the myotendinous junction in a hamstring injury, in turn, increases the risk of re-injury significantly [11]**.** These recent scientific findings highlight the clinical significance of identifying the exact connective tissue structure ruptured in the skeletal muscle.

Then there are the clinical implications related to the connective tissue structure involved. For example, a sprinter with a sudden tendon rupture may require a different management approach than a basketball player with fascial tightness due to overuse. Consequently, a precise understanding of these structures helps tailor rehabilitation strategies and helps athletes return to their sport safely [12, 13].

Understanding the histological variances among tendons, aponeuroses, and fascia and using the nomenclature in the correct way is paramount for the following reasons when attempting to accurately describe and diagnose muscle and tendon injuries in sports [14, 15]:

Injury identification Each structure has a different function and strength, and thus, a different tendency for certain types of injuries. For example, tendons, which are designed for high tensile strength, are more prone to either acute, traumatic tears or chronic degeneration (tendinopathy) from overloading. In contrast, an aponeurosis can disperse force and might be more resilient but can still be injured with excessive multi-directional stresses.

Injury mechanism Understanding the histological structure helps in determining the mechanism of injury. A sudden explosive movement might lead to a tendon, aponeurosis, or myotendinous injury, whilst the fascial tissue does not need a high energy mechanism for injury to occur because the myofascial junction and the fascia itself are weaker than aponeurosis and tendons [3, 4].

Injury prognosis, treatment and recovery Histological structure informs treatment plans. Tendons, being less vascular than muscle tissue, heal slower and might benefit from targeted interventions that enhance blood circulation at the injured site [16]. In contrast, fascial injuries might respond better to manual therapy and stretching due to their different structural properties. Importantly, due to their different healing times and properties (tendons being the slowest to heal and the most prone to re-injury), the prognosis will differ according to the structure affected [17, 18].

Injury prevention Knowledge of these structures contributes to injury prevention. For instance, by knowing that fascia requires multi-directional flexibility, training can incorporate mobility work to prevent fascial restrictions that can lead to an injury.

It is also an issue to consider that all muscles are different in terms of their architecture, and potential distinctions can be found due to anatomical variabilities between individuals.

Another important point to consider is that, if we use the same nomenclature and we can apply these concepts properly, the distinguishing features between these three histological components can also be seen in imaging tests such as ultrasound or, especially, in magnetic resonance imaging (MRI). This would allow the use of the correct terms and nomenclature not just when reporting imaging scans, which is key to obtaining a correct initial and accurate diagnosis (Fig. 2), but also for the reproducibility of actual research on these injuries.

5 Conclusions

Uniform nomenclature based on histological differences allows for clear communication between athletes, coaches, and health care providers, ensuring an accurate understanding of the injury's nature, which is essential for effective

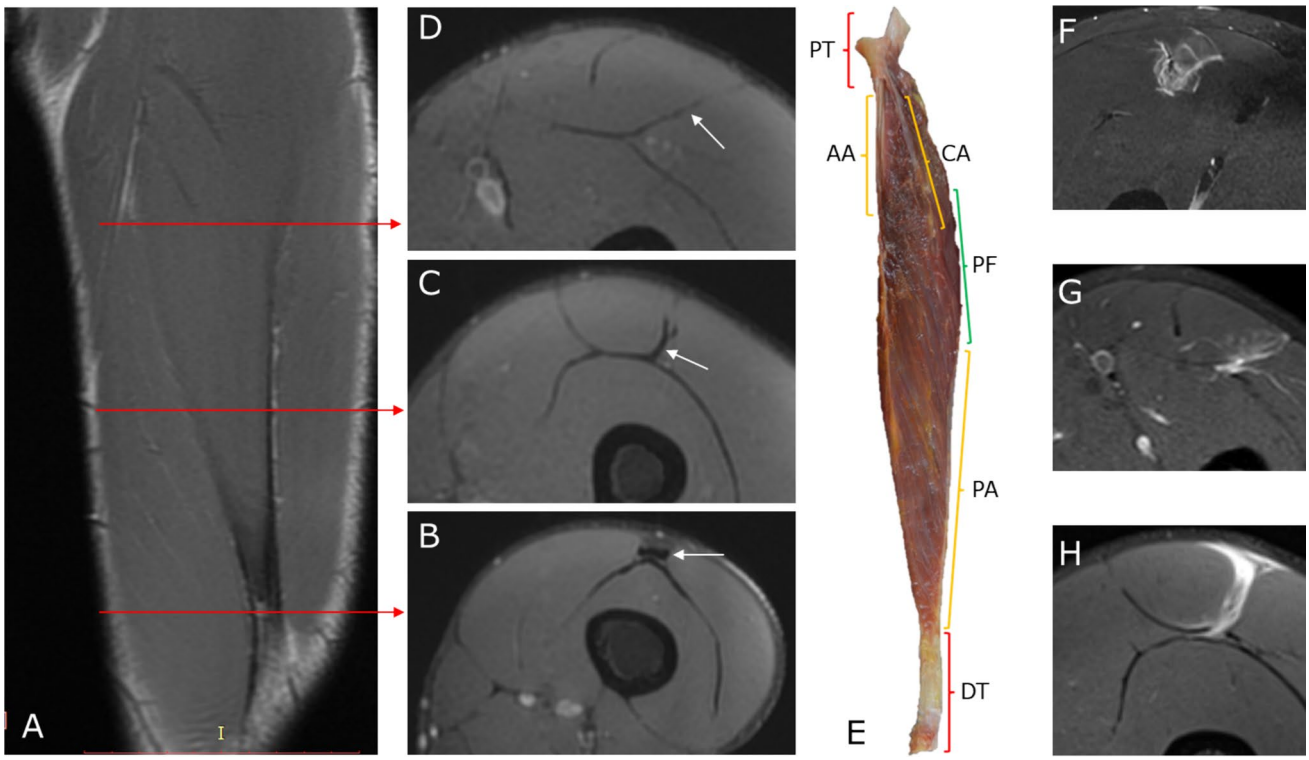

Fig. 2 MRI imaging of connective tissue structures in skeletal muscle. Representative MRI images of rectus femoris (RF) muscle demonstrate the appearance of tendon, aponeurosis, and fascia. Coronal T1 MRI image (**A**) of the entire RF. The arrows show the level of the axial MRI cuts **B**, **C**, and **D**. The axial T1 FatSat images demonstrate the thickness differences between tendon (**B**), aponeurosis (**C**), and fascial tissue (**D**). Example from RF muscle (**B**) shows the RF fascicles for the quadricipital tendon, (**C**) shows the posterior aponeurosis of the RF, and (**D**) shows the posterior fascia of the RF. (**E**) Sagittal view of a cadaveric sample of the human RF. Different connective tissue structures are identified and marked: PT (proximal tendons); AA (anterior aponeurosis); CA (central aponeurosis); PF (posterior fascia); PA (posterior aponeurosis); DT (distal tendon). Images (**F–H**) show a T2 fluid-sensitive MRI sequence of different injury examples. Image of a complete rupture of the RF central aponeurosis (**F**); image of a fascial injury of the RF (**G**), and finally, image of a posterior aponeurosis injury of the RF (**H**). All have different clinical and prognostic implications

treatment and rehabilitation strategies. By focussing on the histological characteristics, there is a layer of specificity added that can significantly refine the approach to diagnosis, prognosis, and treatment of sports-related muscle and tendon injuries not just for the treatment of the athletes, but also for the reproducibility of academic research on these injuries.

Declarations

Funding No sources of funding were used to assist in the preparation of this article.

Conflict of interest The authors declare they have no competing interests or financial interests that are relevant to the content of this article. Carles Pedret is an Editorial Board member of Sports Medicine. This author was not involved in the selection of peer reviewers for the manuscript or any of the subsequent editorial decisions.

Author contributions CP and RB conceived the idea for this article. JP conducted the research for the correct samples and preparations. CP wrote the first draft of the manuscript. RB, JP, and TJ revised the original manuscript. All authors read and approved the final version.

References

1. Mueller-Wohlfahrt H-W, et al. Terminology and classification of muscle injuries in sport: the Munich consensus statement. Br J Sports Med. 2013;47(6):342–50. https://doi.org/10.1136/bjsports-2012-091448.
2. Pollock N, James SLJ, Lee JC, Chakraverty R. British athletics muscle injury classification: a new grading system. Br J Sports Med. 2014;48(18):1347–51. https://doi.org/10.1136/bjsports-2013-093302.
3. Valle X, et al. Muscle injuries in sports: a new evidence-informed and expert consensus-based classification with clinical application. Sports Med. 2017;47(7):1241–53. https://doi.org/10.1007/s40279-016-0647-1.
4. Balius R, et al. Role of the extracellular matrix in muscle injuries: histoarchitectural considerations for muscle injuries. Orthop J Sports Med. 2018;6(9):4–6. https://doi.org/10.1177/2325967118795863.
5. Wohlgemuth RP, Sriram S, Henricson KE, Dinh DT, Brashear SE, Smith LR. Strain-dependent dynamic re-alignment of collagen fibers in skeletal muscle extracellular matrix. Acta Biomater. 2024. https://doi.org/10.1016/j.actbio.2024.08.035.

6. Gillies AR, Lieber RL. Structure and function of the skeletal muscle extracellular matrix. Muscle Nerve. 2011;44(3):318–31. https://doi.org/10.1002/mus.22094.
7. Wheatley BB, Dyer OL, Tully EE, Seeley MA. Aponeurosis structure-function properties: evidence of heterogeneity and implications for muscle function. Acta Biomater. 2023;168:298–308. https://doi.org/10.1016/j.actbio.2023.06.035.
8. Langevin MHM, Huijing PPA. Communicating about fascia: history, pitfalls, and recommendations. Int J Ther Massage Bodyw Res Educ Pract. 2009. https://doi.org/10.3822/ijtmb.v2i4.63.
9. Peña-Amaro J. The musculotendinous transition of the extracellular matrix. Apunts Sports Med. 2021. https://doi.org/10.1016/j.apunsm.2021.100350.
10. Valle X, et al. Return to play prediction accuracy of the MLG-R classification system for hamstring injuries in football players: a machine learning approach. Sports Med. 2022;52(9):2271–82. https://doi.org/10.1007/s40279-022-01672-5.
11. Zein MI, et al. Baseline clinical and MRI risk factors for hamstring reinjury showing the value of performing baseline MRI and delaying return to play: a multicentre, prospective cohort of 330 acute hamstring injuries. Br J Sports Med. 2024. https://doi.org/10.1136/bjsports-2023-107878.
12 Macdonald B, Mcaleer S, Kelly S, Chakraverty R, Johnston M, Pollock N. Hamstring rehabilitation in elite track and field athletes: applying the British Athletics Muscle Injury Classification in clinical practice. Br J Sports Med. 2019. https://doi.org/10.1136/bjsports-2017-098971.
13. Hamilton B, Alonso JM, Best TM. Time for a paradigm shift in the classification of muscle injuries. J Sport Health Sci. 2017;6(3):255–61. https://doi.org/10.1016/j.jshs.2017.04.011.
14. Zügel M, et al. Fascial tissue research in sports medicine: from molecules to tissue adaptation, injury and diagnostics: consensus statement. Br J Sports Med. 2018;52(23):1497. https://doi.org/10.1136/bjsports-2018-099308.
15. Schleip R, Hedley G, Yucesoy CA. Fascial nomenclature: update on related consensus process. Clin Anat. 2019;32(7):929–33. https://doi.org/10.1002/ca.23423.
16. Järvinen TAH. Neovascularisation in tendinopathy: from eradication to stabilisation? Br J Sports Med. 2020;54(1):1. https://doi.org/10.1136/bjsports-2019-100608.
17. Isern-Kebschull J, et al. MRI findings prior to return to play as predictors of reinjury in professional athletes: a novel decision-making tool. Insights Imaging. 2022;13(1):203. https://doi.org/10.1186/s13244-022-01341-1.
18. Järvinen TA, Järvinen M, Kalimo H. Regeneration of injured skeletal muscle after the injury. Muscles Ligaments Tendons J. 2013;3(4):337–45.

Springer Nature or its licensor (e.g. a society or other partner) holds exclusive rights to this article under a publishing agreement with the author(s) or other rightsholder(s); author self-archiving of the accepted manuscript version of this article is solely governed by the terms of such publishing agreement and applicable law.